


## *A Patient's Guide to* **Bunionette (Tailor's Bunion)**



©MMG 2003

---





### Bunionette

©MMG 2001

## Introduction

A *bunionette* is similar to a bunion, but it develops on the outside of the foot. It is sometimes referred to as a *tailor's bunion* because tailors once sat cross-legged all day with the outside edge of their feet rubbing on the ground. This produced a pressure area and callus at the bottom of the fifth toe.

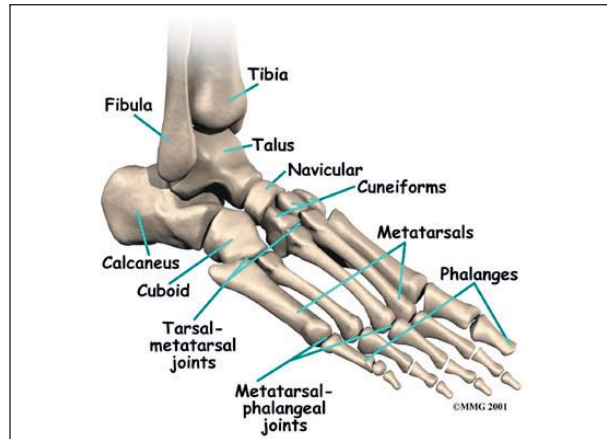
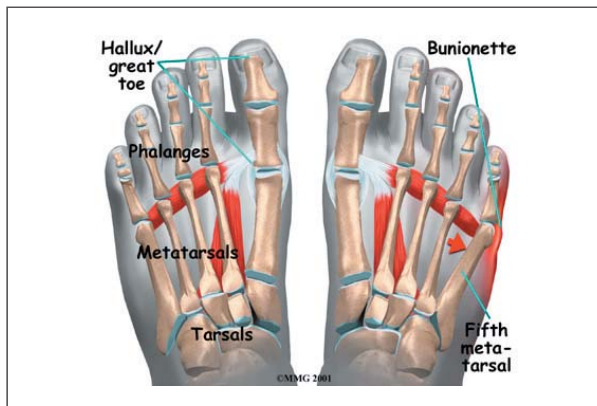
**This guide will help you understand**

- where a bunionette develops
- why a bunionette causes problems
- what can be done to treat a bunionette

## Anatomy

Where does a bunionette develop?

A bunionette occurs over the area of the foot where the small toe connects to the foot.



This area is called the *metatarsophalangeal joint*, or MTP joint. The *metatarsals* are the long bones of the foot. The *phalanges* are the small bones in each toe. The big toe has two phalanges, and the other toes have three phalanges each.

## Causes

How does a bunionette develop?

Today a bunionette is most likely caused by an abnormal bump over the end of the fifth metatarsal (the *metatarsal head*) rubbing on shoes that are too narrow. Some people's feet widen as they grow older, until the foot splays. This can cause a bunion on one side of the foot and a bunionette on the other if they continue to wear shoes that are too narrow. The constant pressure produces a callus and a thickening of the tissues over the bump, leading to a painful knob on the outside of the foot.

Many problems that occur in the feet are the result of abnormal pressure or rubbing. One way of understanding what happens in the foot as a result of abnormal pressure is to view the foot simply. Essentially a foot is made up of hard bone covered by soft tissue that we then put a shoe on top of. Most of the symptoms that develop over time are because the skin and soft tissue are caught between the hard bone on the inside and the hard shoe on the outside.

Any prominence, or bump, in the bone will make the situation even worse over the bump. Skin responds to constant rubbing and pressure

by forming a callus. The soft tissues underneath the skin respond to the constant pressure and rubbing by growing thicker. Both the thick callus and the thick soft tissues under it are irritated and painful. The answer to decreasing the pain is to remove the pressure. The pressure can be reduced from the outside by changing the pressure from the shoes. The pressure can be reduced from the inside by surgically removing any bony prominence.

## Symptoms

What do bunionettes feel like?

The symptoms of a bunionette include pain and difficulty buying shoes that will not cause pain around the deformity. The swelling in the area causes a visible bump that some people find unsightly.

## Diagnosis

How do doctors identify a bunionette?

The diagnosis of a bunionette is usually obvious on physical examination. X-rays may help to see if the foot has splayed and will help decide what needs to be done if surgery is necessary later.

## Treatment

What can be done for a bunionette?

### Nonsurgical Treatment

Treatment initially is directed at obtaining proper shoes that will accommodate the width of the forefoot. Pads over the area of the bunionette may help relieve some of the pressure and reduce pain. These pads are usually sold in drug and grocery stores. They are small and round with a hole in the middle, like a small doughnut.

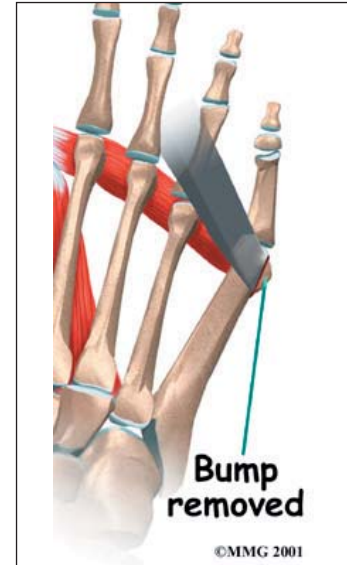
### Surgery

If all else fails, surgery may be recommended to reduce the deformity. Surgery usually involves removing the prominence of bone

underneath the bunion to relieve pressure. Surgery may also be done to realign the fifth metatarsal if the foot has splayed.

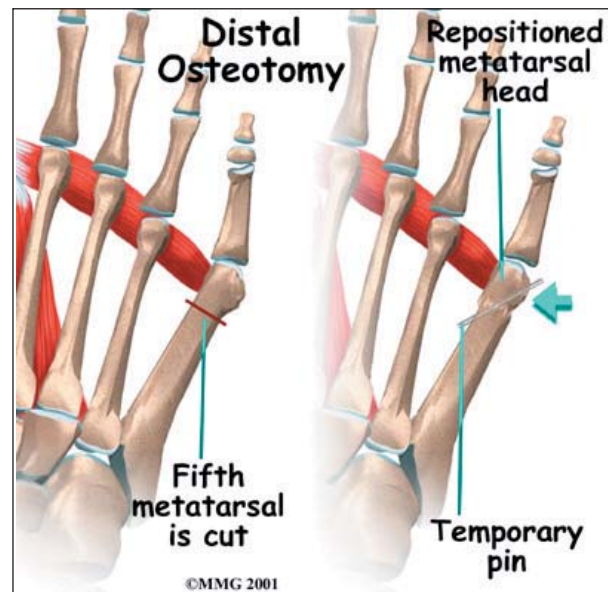
### Bunionette Removal

To remove the prominence, the surgeon makes a small incision in the skin over the bump. The bump is then removed with a small chisel, and the bone edges are smoothed. Once enough bone has been removed, the skin is closed with small stitches.



### Distal Osteotomy

If your doctor decides that the angle of the metatarsal is too great, the fifth metatarsal bone may be cut and realigned. This is called an *osteotomy*. Once the surgeon has performed the osteotomy, the bones are realigned and held in position with metal pins. The metal pins remain in place while the bones heal.



## Rehabilitation

What should I expect after treatment?

### Nonsurgical Rehabilitation

Patients with a painful bunionette may benefit from four to six physical therapy treatments. Your therapist can offer ideas of shoes that have a wide forefoot, or *toe box*. The added space in this part of the shoe keeps the metatarsals from getting squeezed inside the shoe. A special pad can also be placed over the bunionette.

These simple changes to your footwear may allow you to resume normal walking immediately, but you should probably cut back on more vigorous activities for several weeks to allow the inflammation and pain to subside.

Treatments directed to the painful area help control pain and swelling. Examples include ultrasound, moist heat, and soft-tissue massage. Therapy sessions sometimes include *iontophoresis*, which uses a mild electrical current to push anti-inflammatory medicine to the sore

area. This treatment is especially helpful for patients who can't tolerate injections.

### After Surgery

Patients are usually fitted with a *post-op shoe*. This shoe has a stiff, wooden sole that protects the toes by keeping the foot from bending. Any pins are usually removed after the bone begins to mend (usually three or four weeks). You will probably need crutches briefly after surgery, and a therapist may be consulted to help you use your crutches.

You will probably wear a bandage or dressing for about a week following the procedure. The stitches are generally removed in 10 to 14 days. However, if your surgeon chose to use sutures that dissolve, you won't need to have the stitches taken out.

During your follow-up visits, X-rays will probably be taken so that the surgeon can follow the healing of the bones and determine how much correction has been achieved.

## Notes